CHEST INJURY

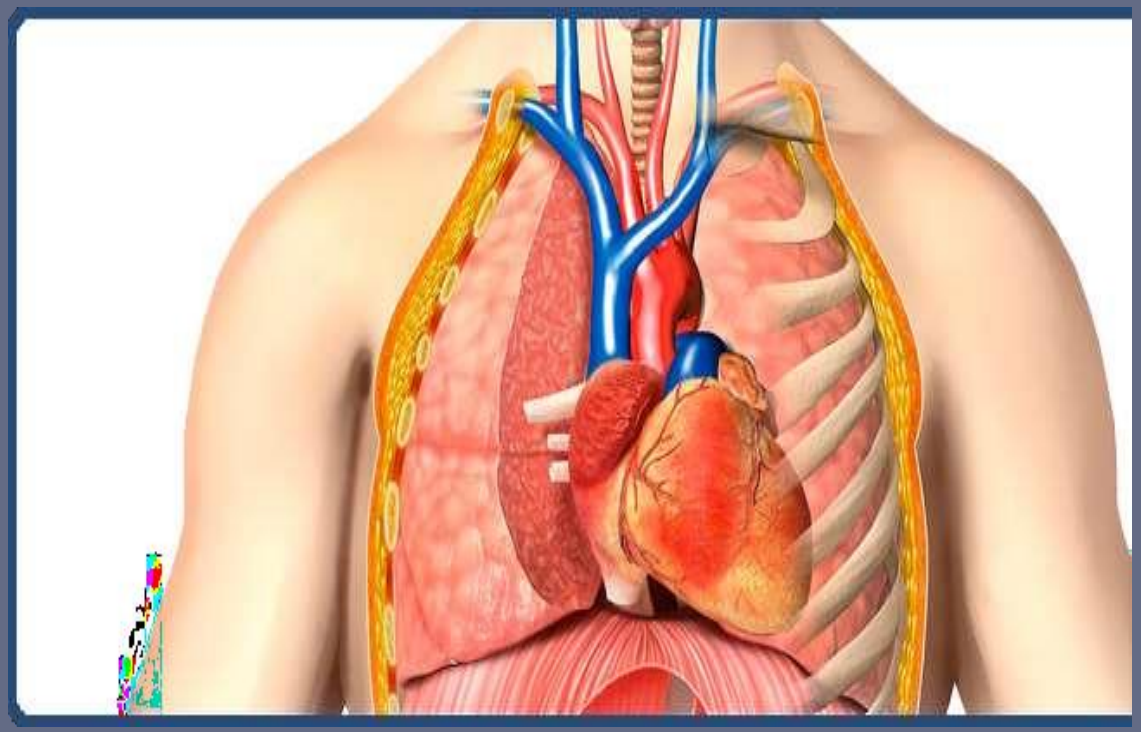

PRESENTED BY:-
BHAGAWATI RAY

Introduction

Introduction:

- Traumatic injuries to the chest contribute to 75% of all traumatic deaths.
- Thoracic injuries range from simple rib fractures to complex life-threatening rupture of organs.
- The mechanisms of injuries causing chest trauma are separated into two categories: blunt trauma and penetrating trauma.

- Chest injuries are potentially life-threatening because of immediate disturbances of cardiorespiratory physiology and haemorrhage and later developments of infection, damaged lung and thoracic cage.

Definition

Definition:

- A chest injury is define as, “it is a form of injury to the chest including the ribs, heart and lungs, great vessels, trachea and esophagus.”

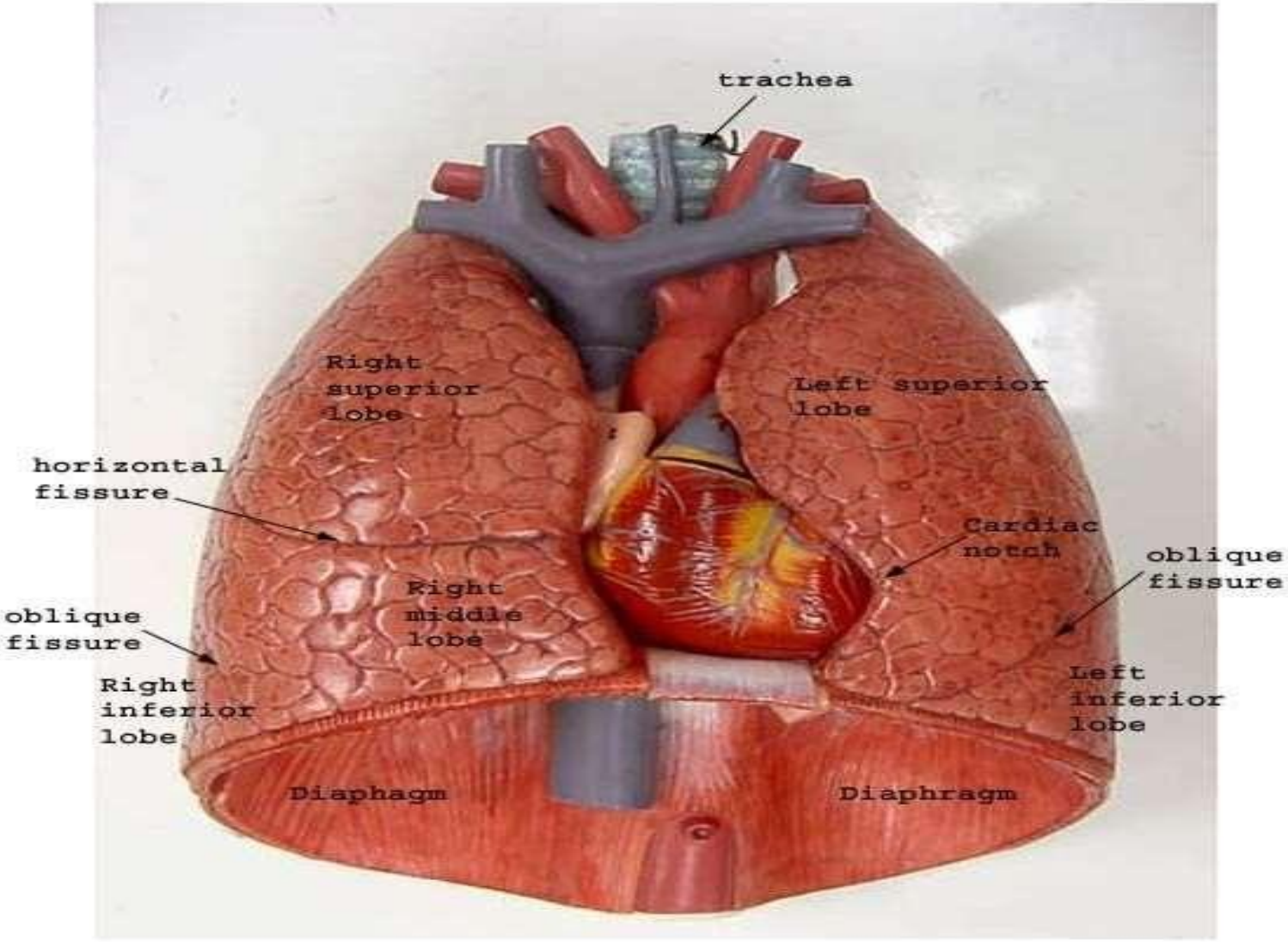
trachea
Right superior lobe
Left superior lobe
horizontal fissure
Cardiac notch
oblique fissure
Right middle lobe
oblique fissure
Right inferior lobe
Left inferior lobe
Diaphagm
Diaphragm

Incidence

Incidence:

- 25% of all death form traumatic injury.

Causes

Causes:

BLUNT INJURY CAUSES

PENETRATING INJURY CAUSES

Blunt Trauma to the Chest

BLUNT INJURY CAUSES:

- Motor vehicle accident
- Pedestrian accident
- Fall
- Sports injury
- Assault with blunt object or Altercations
- Crush injury
- Explosion

PENETRATING INJURY CAUSES:

- Knife
- Gunshot
- Stick
- Arrow
- Occupational injury

Types of chest injuries

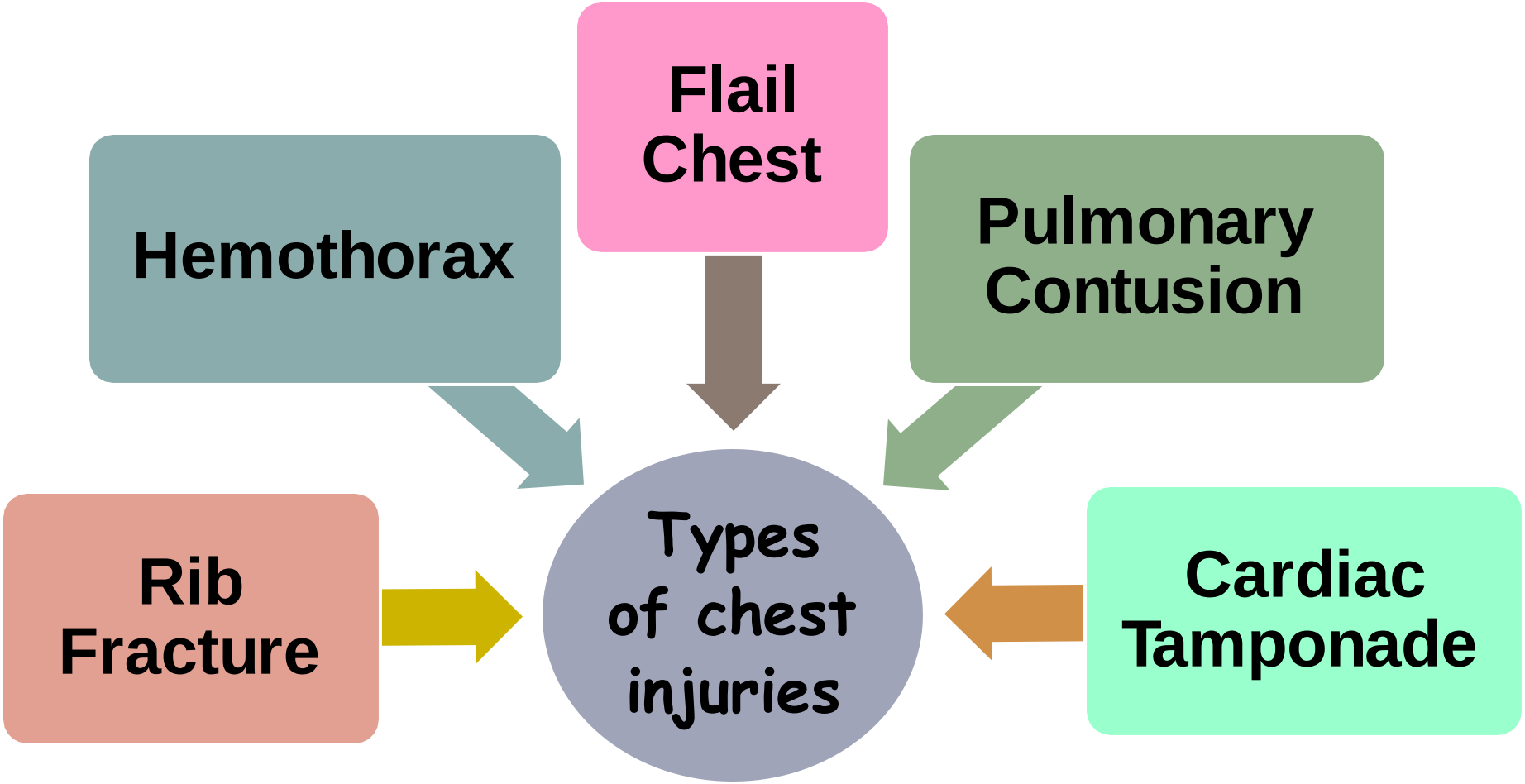
Flail Chest
Hemothorax
Pulmonary Contusion
Rib Fracture
Types of chest injuries
Cardiac Tamponade

Rib Fracture:

- Most common chest injury.
- May interfere with ventilation and may lacerate underlying lung.

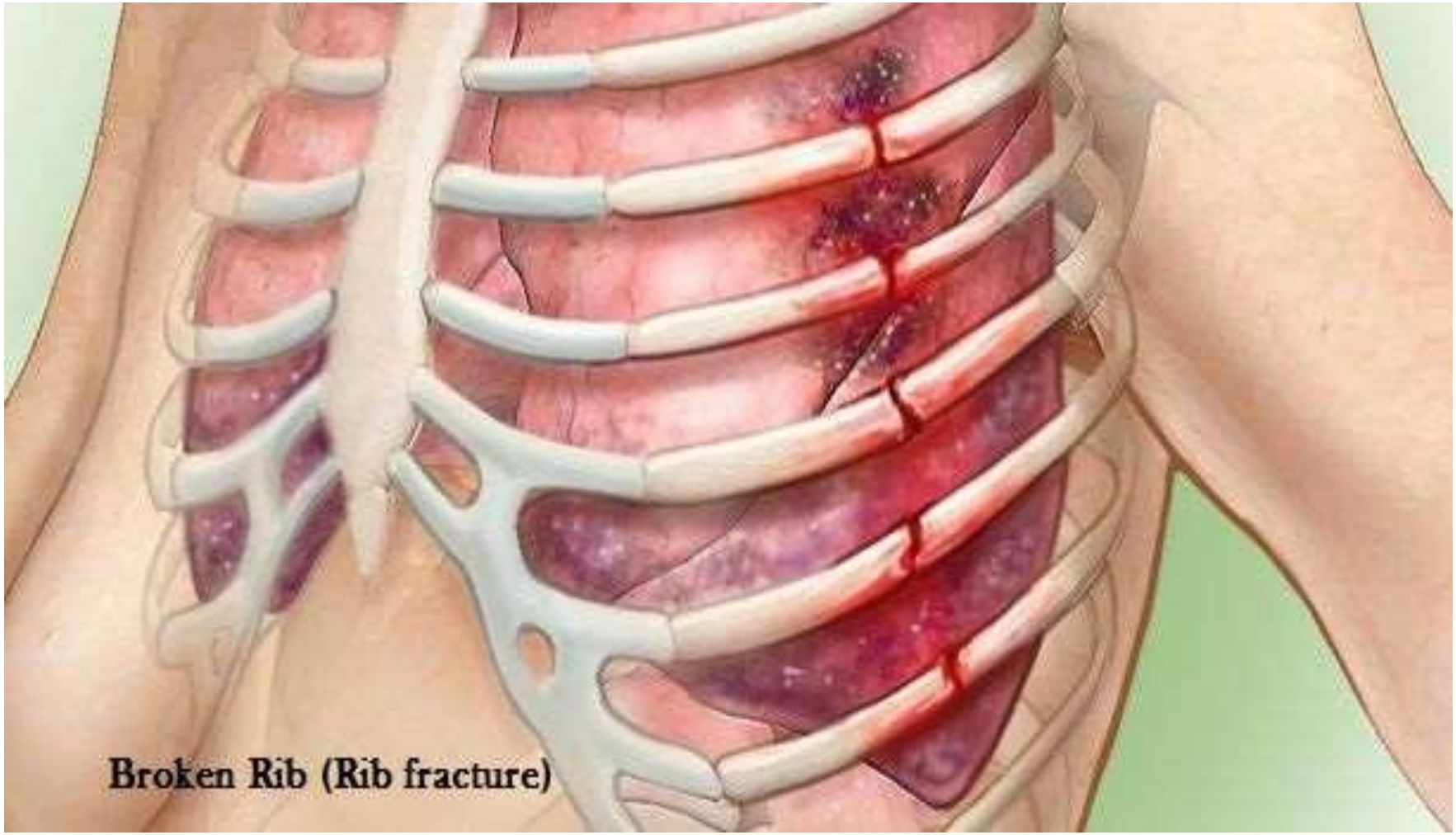
Broken Rib (Rib fracture)

Hemothorax:

- Blood in pleural space as a result of penetrating or blunt chest trauma.
- Accompanies a high percentage of chest injuries.
- Can result in hidden blood loss.

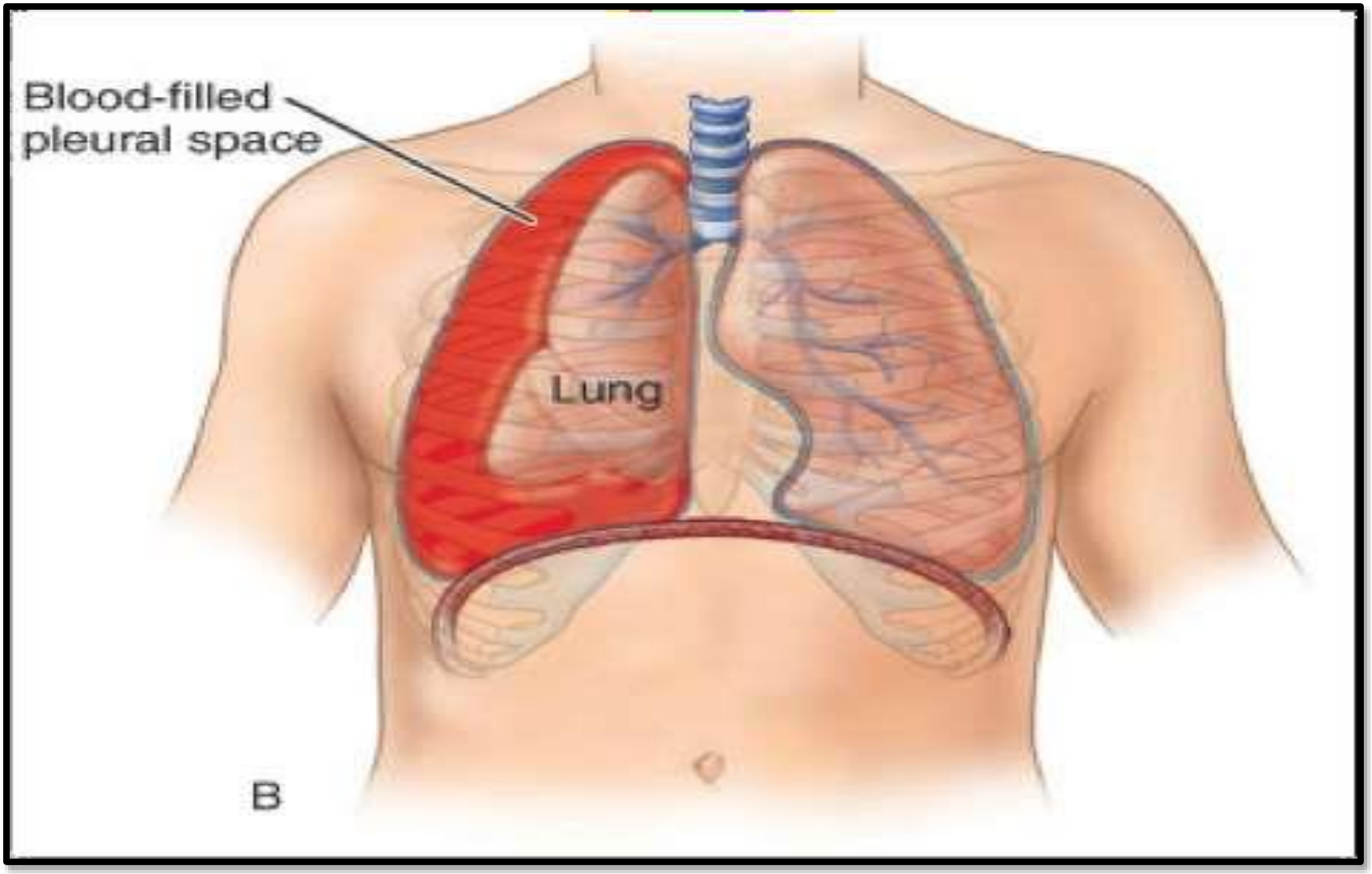
Blood-filled
pleural space
Lung
B

Hemothorax

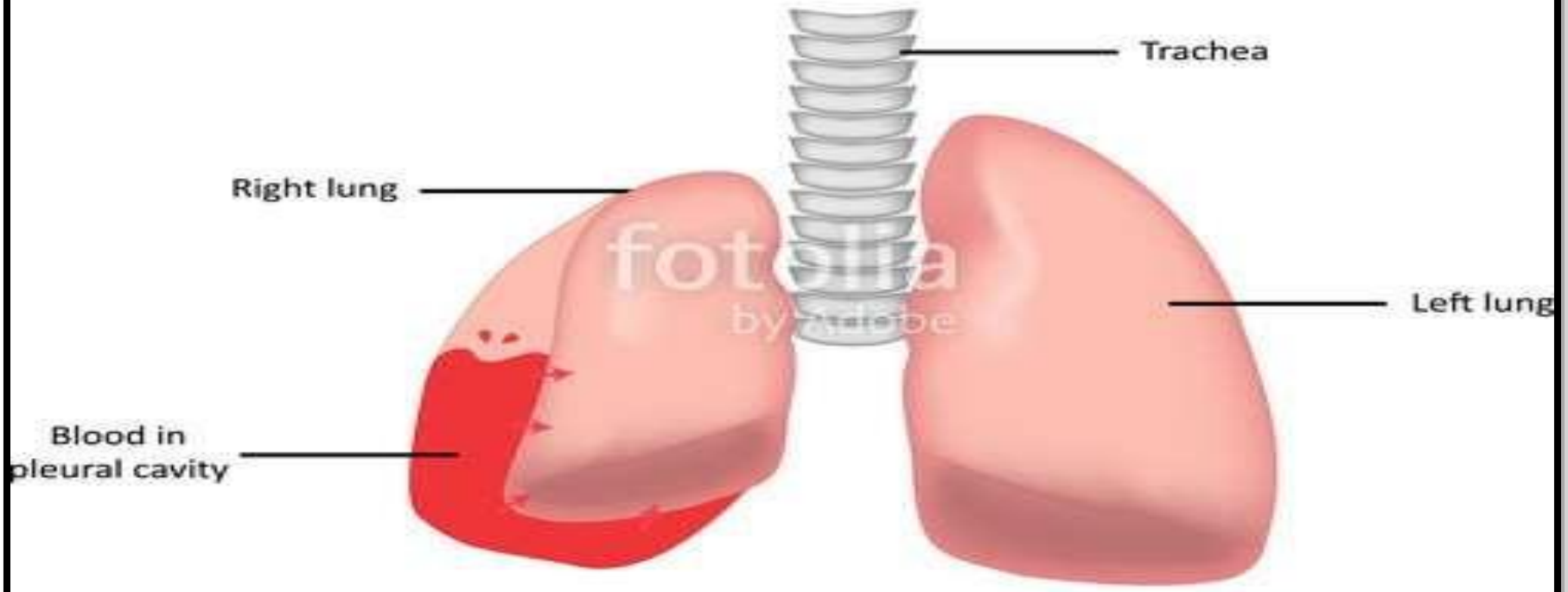

Flail Chest:

- Loss of stability of chest wall as a result of multiple rib fractures, or combined rib and sternum fractures.
- When this occurs, one portion of the chest has lost its bony connection to the rest of the rib cage.

- During respiration, the detached part of the chest will be pulled in on inspiration and blown out on expiration **(PARADOXICAL MOVEMENT)**
- Normal mechanics of breathing are impaired to a degree that seriously jeopardizes ventilation, causing dyspnea and cyanosis.

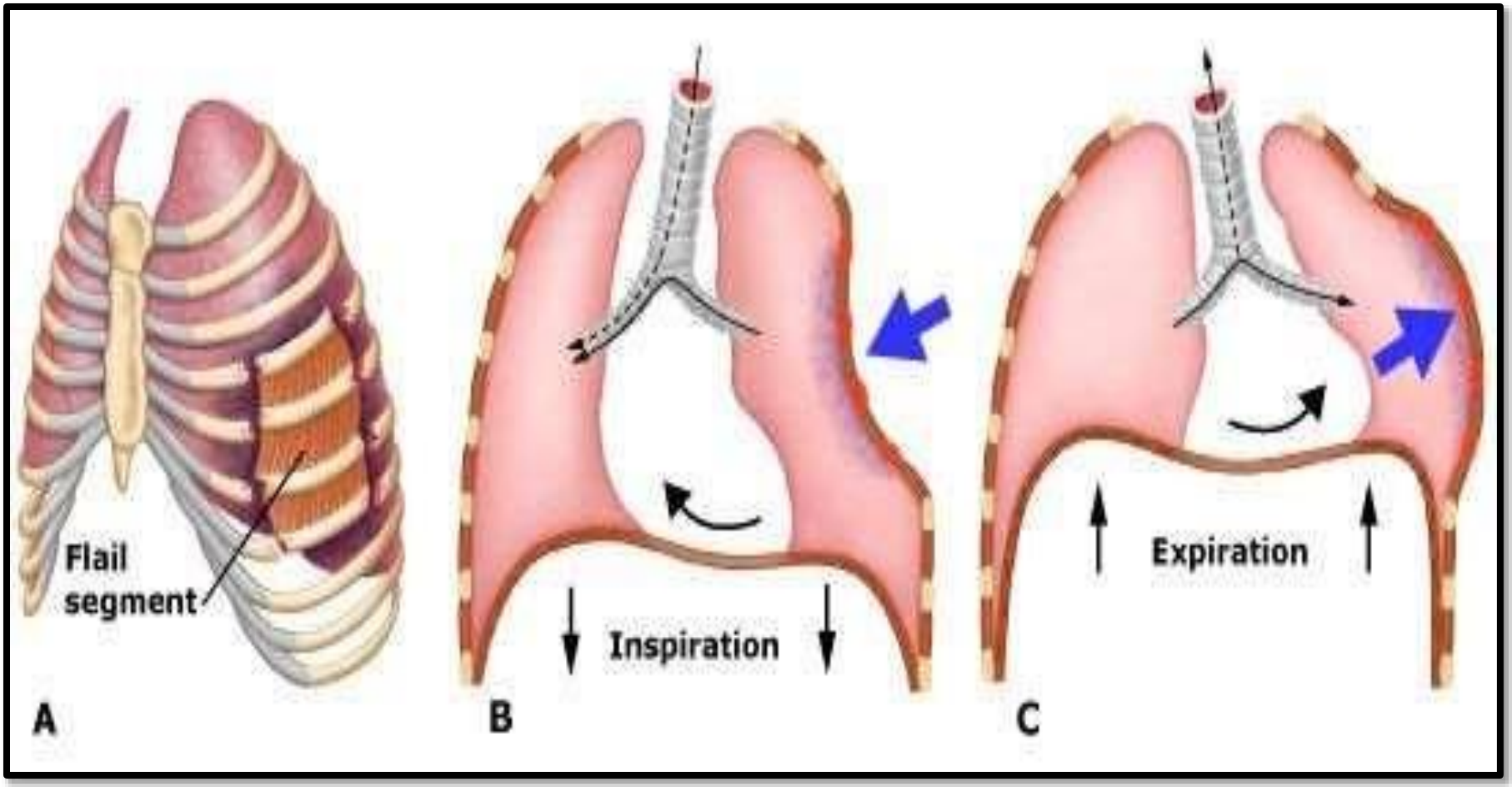
Flail
segment
A
Inspiration
B
Expiration
C

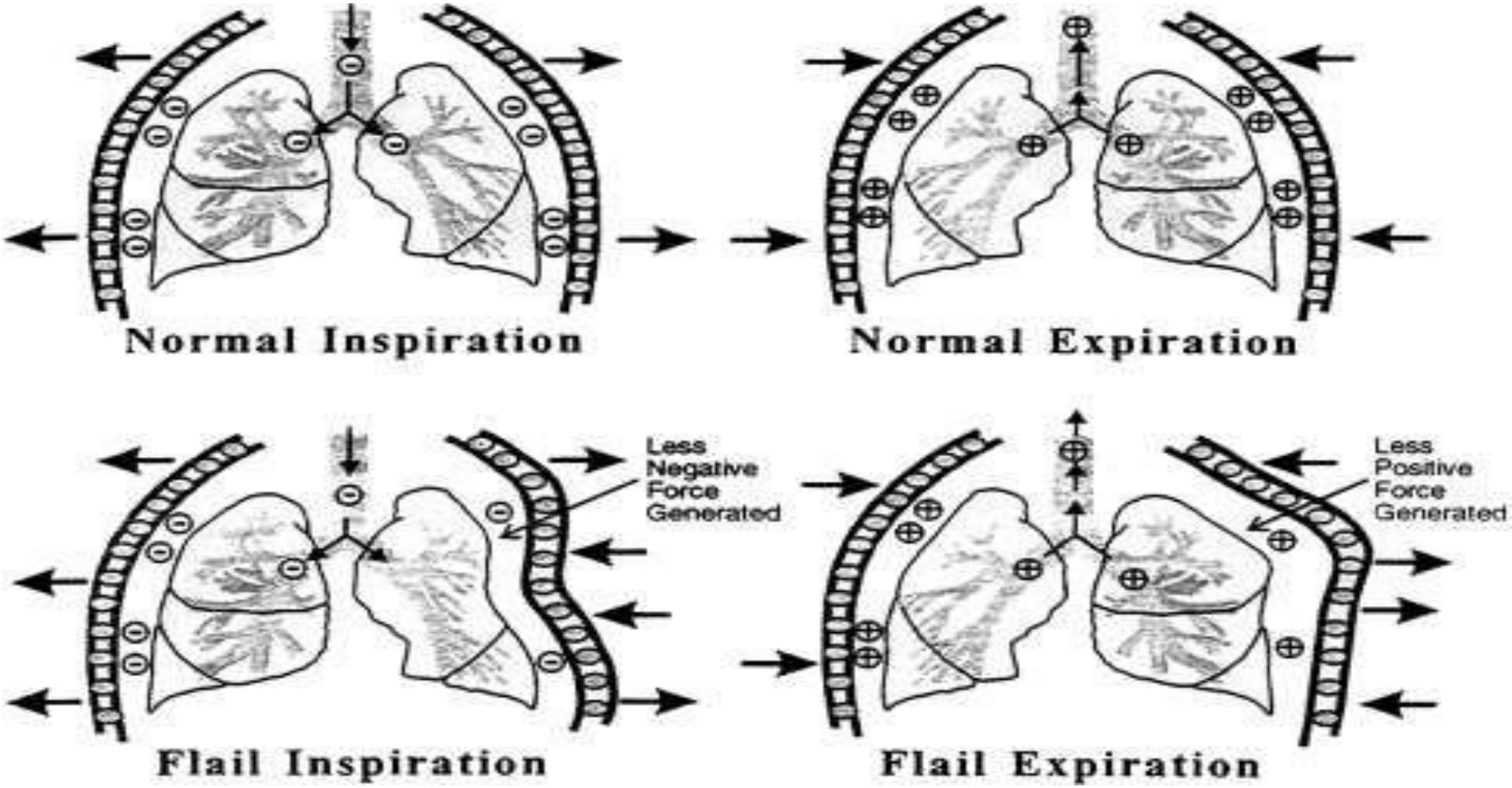
Normal Inspiration
Normal Expiration
Less Negative Force Generated
Less Positive Force Generated
Flail Inspiration
Flail Expiration

Pulmonary Contusion:

- Bruise of the lung parenchyma those results in leakage of blood and edema fluid into the alveolar and interstitial spaces of the lung.
- May not be fully developed for 24 to 72 hours.

[redacted]: Thoracic Injuries

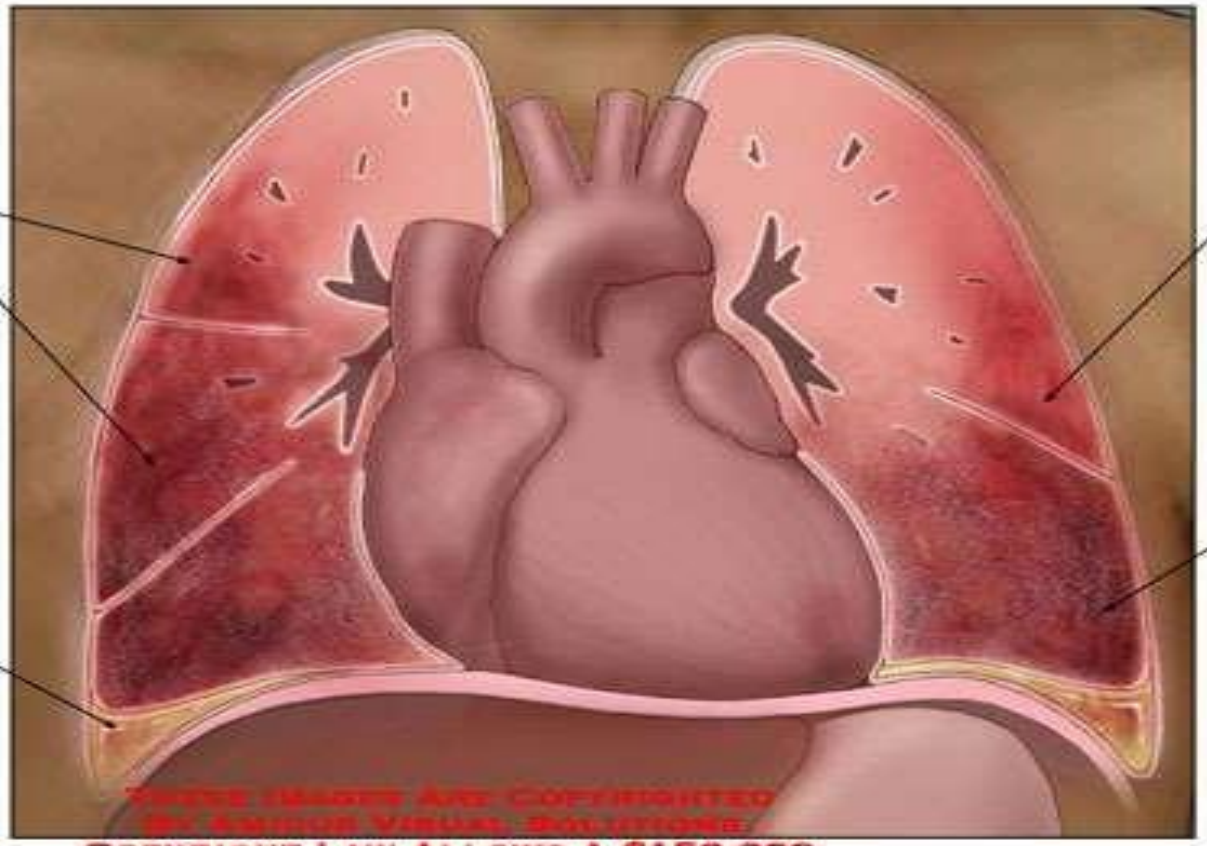

Cardiac Tamponade:

- Compression of the heart as a result of accumulation of fluid within the pericardial space.
- Caused by penetrating injuries, metastasis, and other disorders.

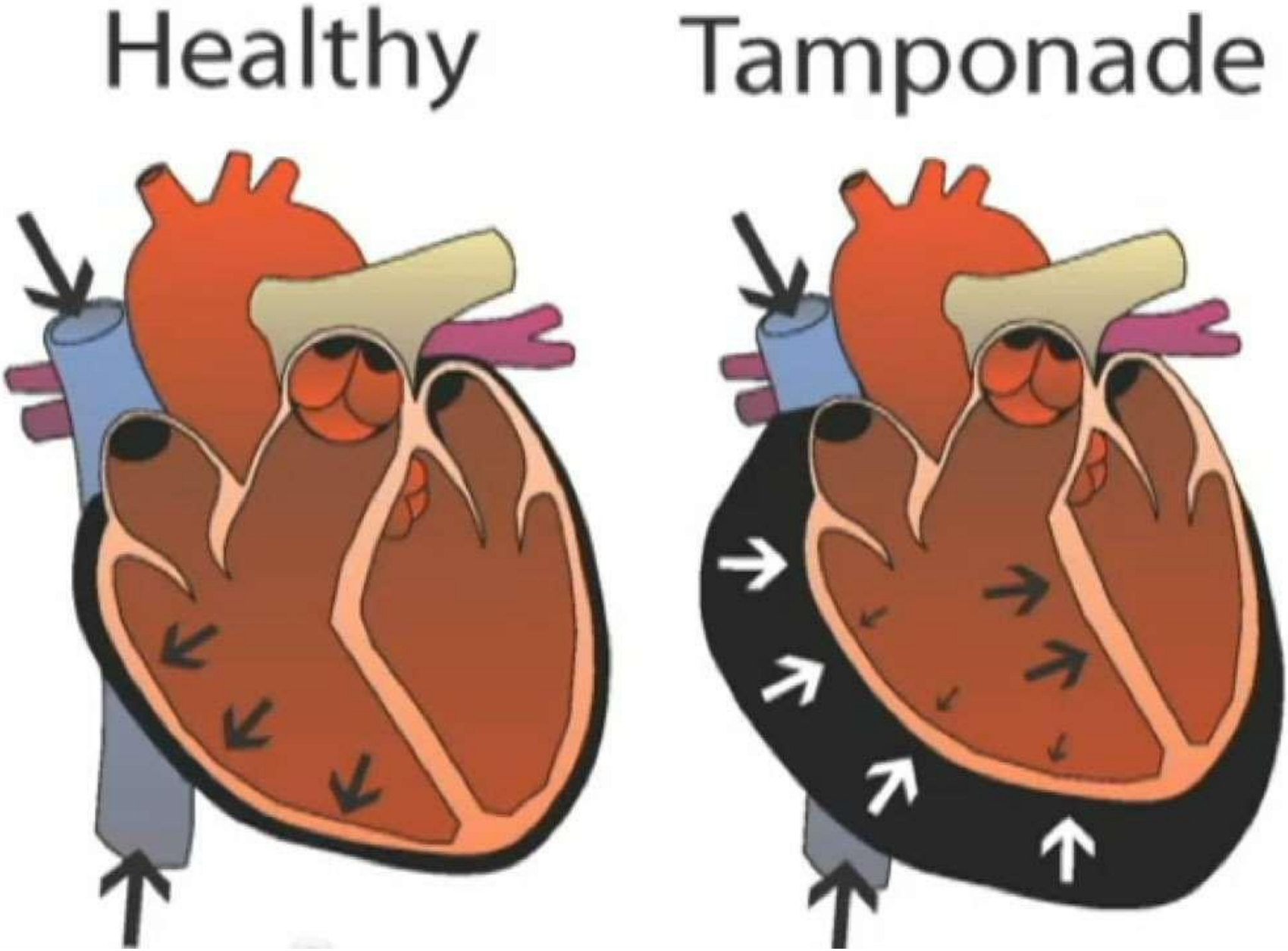
Healthy
Tamponade

Clinical manifestation:

Respiratory

- Dyspnea, respiratory distress
- Cough with or without haemoptysis
- Cyanosis of mouth, face, nail beds, mucous membranes
- Tracheal deviation
- Audible air escaping from chest wound
- Decreased breath sounds on side of injury
- Decreased O2 saturation
- Frothy secretions

Cardiovascular

- Rapid, thready pulse
- Decreased BP
- Narrowed pulse pressure
- Asymmetric BP values in arms
- Distended neck veins
- Muffled heart sounds

- Chest pain
- Crunching sound synchronous with heart sounds
- Dysrhythmias

Surface Findings

- Bruising
- Abrasions
- Open chest wound
- Asymmetric chest movement
- Subcutaneous emphysema

Diagnostic evaluation

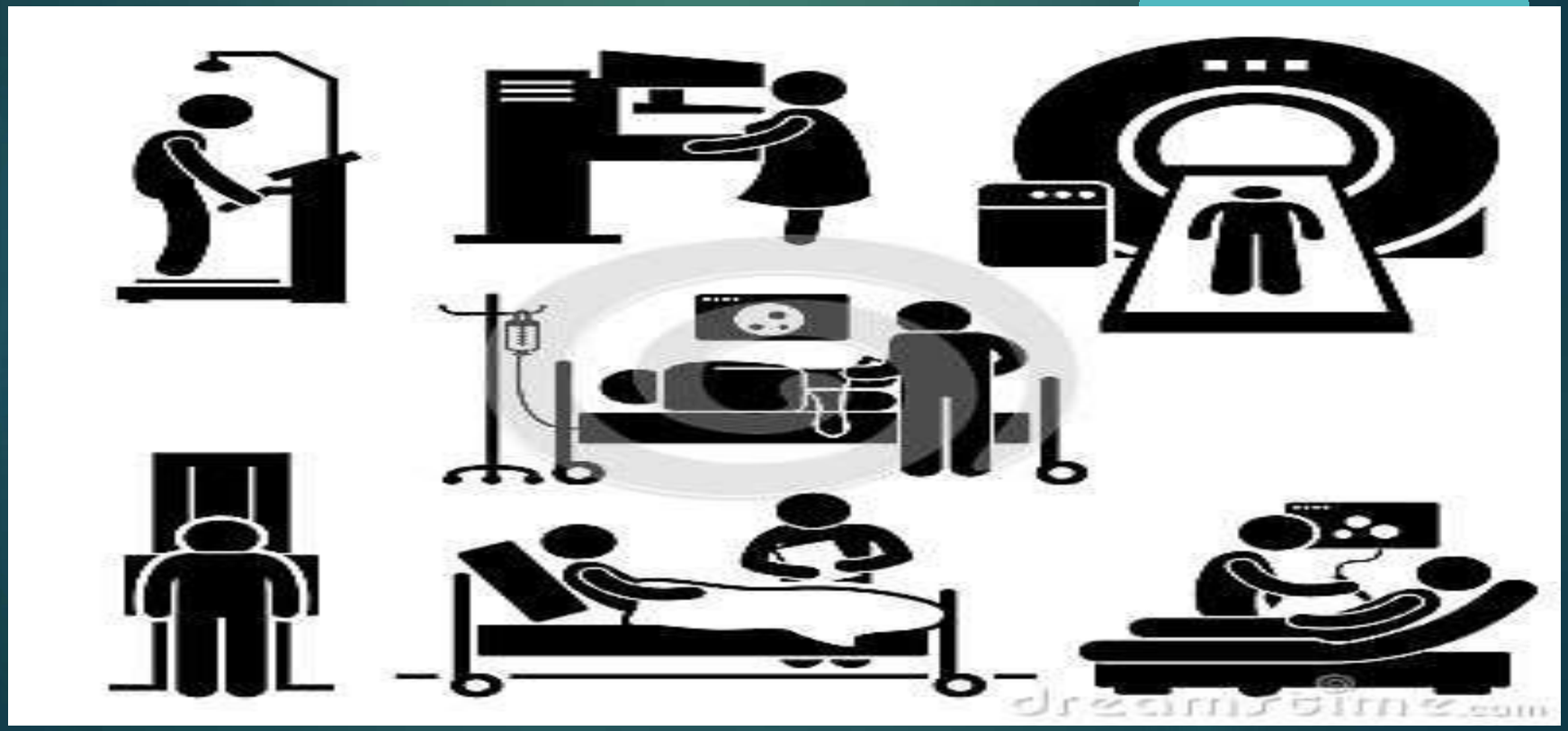

- **History collection**
- **Physical examination**
- While doing physical examination assess for abdominal tenderness, chest tenderness, chest bruising, chest swelling, decrease lung sound, wheezing, rapid pulse and rapid breathing, chest crepitation, cyanosis, dyspnea.
- X- Ray
- CT Scan and MRI

Management

- The **goal** is to restore normal **cardiorespiratory** function as quickly as possible.
- This is accomplished by,
  - Performing effective resuscitation
  - While simultaneously assessing the patient,
  - Restoring chest wall integrity,
  - Reexpanding the lung.

- Assist with intercostal nerve block to relieve pain so coughing and deep breathing may be accomplished. An **intercostal nerve block is the injection of a local anesthetic** into the area around the intercostal nerves to relieve pain temporarily after rib fractures, chest wall injury, or thoracotomy.
- For multiple rib fractures, **epidural anesthesia** may be used.

Rib Fracture:

- Give analgesics (usually nonopioid) to assist in effective coughing and deep breathing.
- Encourage deep breathing with strong inspiration; give local support to injured area by splinting with hands.

Hemothorax:

- Assist with **thoracentesis** to aspirate blood from pleural space, if being done before a chest tube insertion.
- Assist with **chest tube insertion** and set up drainage system for complete and continuous removal of blood and air.
  - Auscultate lungs and monitor for relief of dyspnea.
  - Monitor amount of blood loss in drainage.
- Replace volume with I.V. fluids or blood products.


Pleural
effusion
www.atoznursing.com

Flail Chest:

- Stabilize the flail portion of the chest with hands; apply a pressure dressing and turn the patient on injured side, or place 10-lb sandbag at site of flail.
- Thoracic epidural analgesia may be used for some patients to relieve pain and improve ventilation.

Pulmonary Contusion:

- Employ mechanical ventilation to keep lungs inflated.
- Administer diuretics to reduce edema.
- Correct metabolic acidosis with I.V. sodium bicarbonate.
- Use PAP monitoring.
- Monitor for development of pneumonia.

- If respiratory failure is present, prepare for immediate **ET intubation** and mechanical ventilation treats underlying pulmonary contusion and serves to stabilize the thoracic cage for healing of fractures, improves alveolar ventilation, and restores thoracic cage stability and intrathoracic volume by decreasing work of breathing.
- Prepare for **operative stabilization** of chest wall in select patients.

Cardiac Tamponade:

- Assist with **pericardiocentesis** to provide emergency relief and improve hemodynamic function until surgery can be undertaken.
- Prepare for emergency **thoracotomy** to control bleeding and to repair cardiac injury.

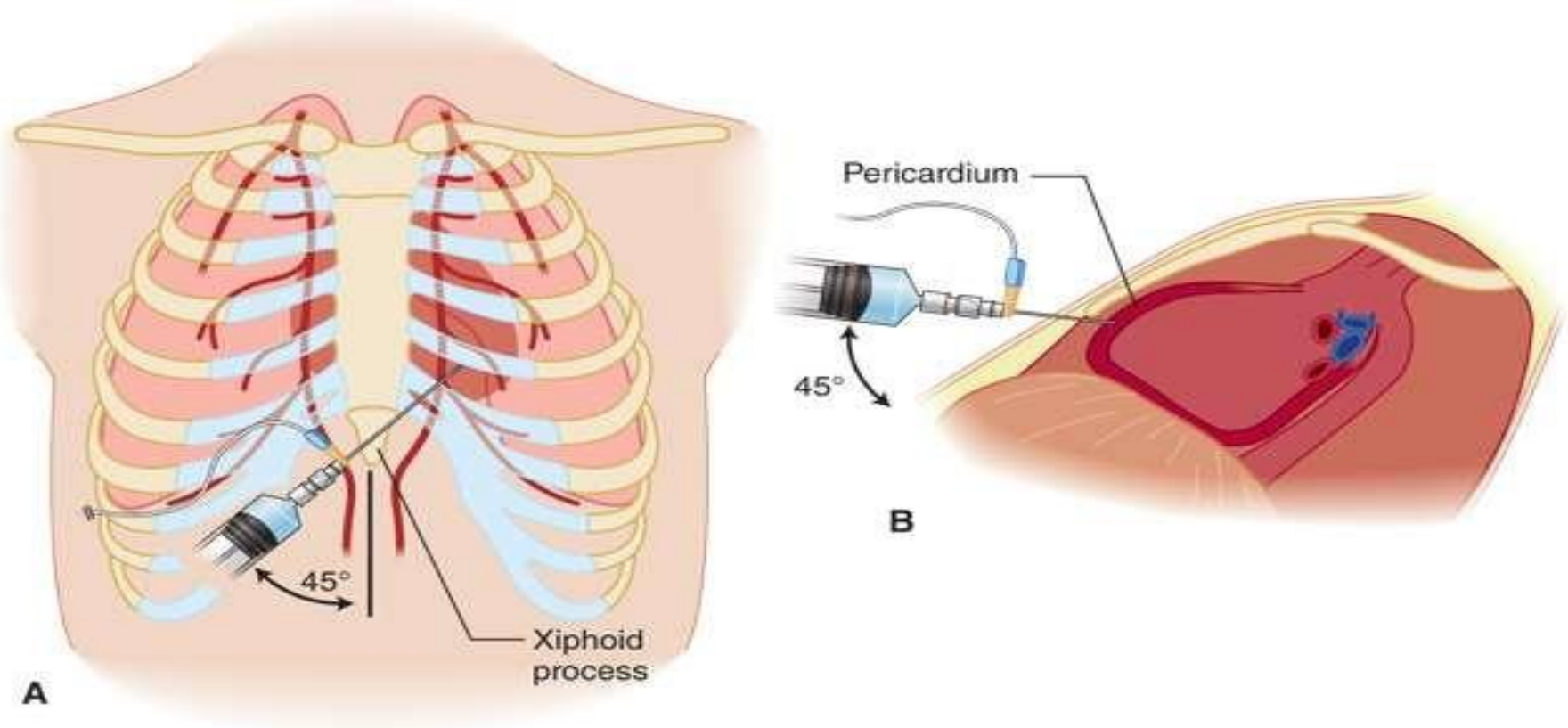

Source: J.E. Tintinalli, J.S. Stapczynski, O.J. Ma, D.M. Yealy, G.D. Meckler, D.M. Cline: Tintinalli's Emergency Medicine: A Comprehensive Study Guide, 8th Edition
www.accessmedicine.com

ADDITIONAL RESPONSIBILITIES:

- Secure and support the airway as indicated.
- Prepare for tracheostomy if indicated.

  Tracheostomy helps to clear tracheobronchial tree, helps the patient breathe with less effort, decreases the amount of dead airspace in the respiratory tree, and helps reduce paradoxical motion.

- When used with mechanical ventilation, provides a closed system and stabilizes the chest.

- Secure one or more I.V. lines for fluid replacement, and obtain blood for baseline studies, such as hemoglobin level and hematocrit.
- Monitor serial CVP readings to prevent hypovolemia and circulatory overload.
- Monitor ABG/Spo_2

- Obtain urinary output hourly to evaluate tissue perfusion.
- Continue to monitor thoracic drainage to provide information about rate of blood loss, whether bleeding has stopped, whether surgical intervention is necessary.

- Institute ECG monitoring for early detection and treatment of cardiac dysrhythmias (dysrhythmias are a frequent cause of death in chest trauma).

- Maintain ongoing surveillance for complications:
  - Aspiration
  - Atelectasis
  - Pneumonia
  - Mediastinal/subcutaneous emphysema
  - Respiratory failure

Patient education and health maintenance:

- Instruct patient in splinting techniques.
- Make sure patient is aware of importance of automobile seat belt use to reduce serious chest injuries caused by automobile accidents.
- Teach patient to report signs of complications increasing dyspnea, fever, and cough.

Thank You!!!