CANCER
SCIENCE
CELL
BACTERIA
HAIR
ANATOMY
MEDICINE
HEALTH
SKIN
DERMIS
MEDICAL
DISEASE
ANATOMICAL
ORGAN
BLOOD
ILLNESS
PAIN
SCIENTIFIC
CELLS
DERMATOLOGY
PATHOLOGY
BIOLOGY
DIAGNOSIS
CONDITION
LAYER
GROWTH
VEIN
ARTERY
PROBLEM
EPIDERMIS
BODY
INFECTION
HUMAN
TREATMENT
TISSUE
SENSORY
VIRUS
TUMOR
CARE
HEALTHCARE

When describing a skin lesion,it is important to note the following features:-

- 1)size
- 2)type
- 3)shape and symmetry
- 4)colour and pigmentation
- 5)surface area
- 6)Distribution over the body surface

Types of lesion

Basic skin lesions are broadly categorized as :

1. Primary
2. Secondary
3. special

- **Primary lesions** :- Basic reaction patterns of skin with a definite morphology.

- **Secondary lesion :-** Develop during the evolutionary process of skin disease or are created by scratching or infection.

- **special skin lesion** :- Specific for certain disease.

Primary Skin Lesions

- Macule
- Patch
- Papule
- plaque
- nodule
- Vesicle
- Bulla
- Pustule
- Abscess
- Wheal
- Cyst

Macule

- A flat circumscribed lesion showing change in color without change in its consistency. Macules are non-palpable.
- They are 0.5cm-1cm in size.
- Discoloration may be brown, blue ,red and hypopigmented or hyperpigmented

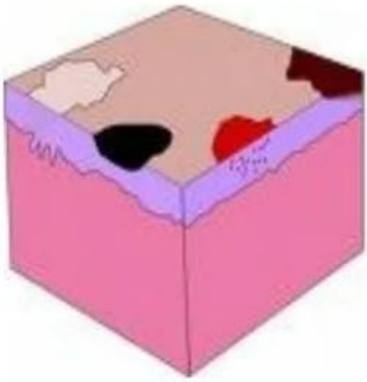

Brown coloured macules

Beckers neveus

Freckle

Fixed drug eruption

Cafe-au-lait spot

Blue coloured macules

Mongolian spot

Blue naevus

ink(tattoo)

Red coloured macules

Drug eruptions

Secondary syphilis

Hypopigmented

Tinea versicolor

PATCH

- A large macule is called patch (>1cm in size).
- May have scaling.
- Eg :- Vitiligo, melasma, pityriasis alba

Papule

- A small, solid lesion, <0.5 cm in diameter, raised above the surface of surrounding skin & hence palpable.
- Papules may be of various colors.

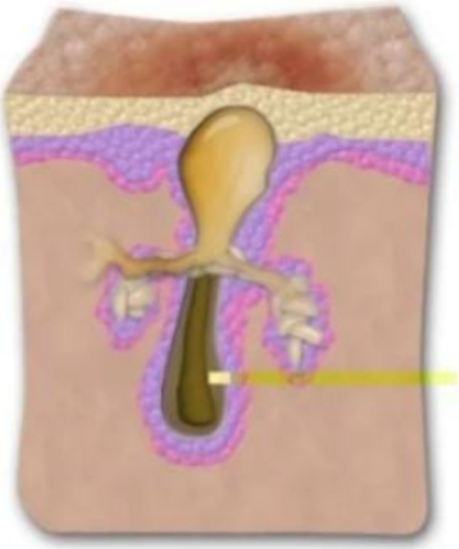

Flesh colored,yellow or white colored papules

Molluscum contagiosum

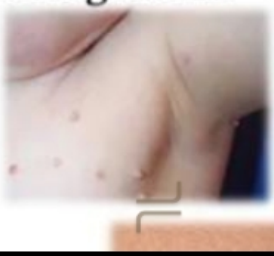

Skin tags

Brown colored papules

Melanoma

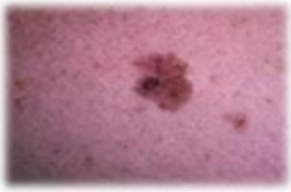

Dermatofibroma

Red colored papule

Acne

folliculits

- **Insect bite**

Blue colored papules

Blue nevus

Lichen planus violaceous papules)

Plaque

- It is an indurated area of skin larger than 0.5 cm in diameter which may be raised or depressed from skin surface.

Examples of plaque

Psoriasis

Lichen planus

Tinea corporis

Other examples of plaque

- Pityriasis rosea
- Seborrheic dermatitis
- Tinea pedis
- Eczema

Nodule

- A large (0.5 – 5.0 cm), firm lesion raised above the surface of surrounding skin.
- It is the depth of involvement that differentiates a nodule from a large papule.
- Could be warm, soft,fluctuant,movable,fixed or painful.
- Surface-smooth,keratotic,ulcerated or fungating.

Examples of nodule

Basal cell carcinoma

Hemangioma

Prurigo nodularis

neurofibromatosis

Other examples of nodule

- Xanthoma
- Keratoacanthoma
- Melanoma

Vesicle

- A small, fluid filled lesion, <0.5 cm in diameter, raised above the plane of surrounding skin. Fluid is often visible and the lesions are translucent

Examples of vesicle

Chicken pox

Herpes zoster

Other examples of vesicle

- Impetigo
- Insect bite
- Herpes simplex
- Dermatitis herpetiformis

bulla

- A fluid filled, raised, often a translucent lesion >0.5cm in diameter

Examples of bulla

Bullous pemphigoid

Fixed drug reaction

Pustule

- A vesicle filled with pus
- It is formed due to collection of inflammatory exudate rich in leucocytes.
- It may contain bacteria or may be sterile.

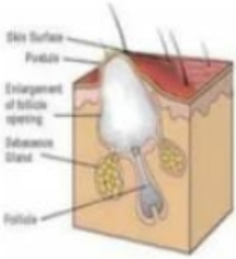

Acne

Pustular psoriasis

Folliculitis

Scabies

Abscess

- A localized collection of pus deep in dermis or subcutaneous tissue
- Due to deep seated location pus may not be visible on skin surface but would show sign of inflammation.

Wheal

- It is a transient swelling of skin disappearing within 24 hrs.
- It is formed due to sudden extravasation of fluid in the dermis.
- Eg: urticaria

Examples of wheal

Urticaria

dermographism

Cyst

- It is a spherical or oval sac or an encapsulated cavity containing fluid or semi solid material.
- It is lined with true epithelium.
- Eg:- mucous retention cyst