Pulse

- A is an index of the heart's rate and rhythm.
- Pulse rate is the number of heart beats per minute.
- With each beat the heart's left ventricle contracts and forces blood into the aorta. This forceful ejection of blood produces a wave that is transmitted through the arteries to the periphery of the body.
- The pulse is a transient expansion of an artery resulting from internal pressure changes.
- The pulse wave is influenced by the elasticity of the larger vessels, body viscosity and arteriolar and capillary resistance.

Characteristics of the Pulse and Alteration in Pulse

While taking pulse, following points must be observed, i. e, rhythm, volume and tension of the pulse.

- **Pulse Rate**: Rate means number of pulse in one minute. The normal range is 60-80 beats per minute and average is about 72 beats per minute. The pulse rate changes with change in age group.

Pulse rate per minute of different age groups

- ✓ Infant 120-160 beats/min.
- ✓ Toddler 90-140 beats/min.
- ✓ Preschooler 80-110 beats/min.
- ✓ School age child 75-100 beats/min
- ✓ Adolescent 60-90 beats/min.
- ✓ Adult 60-100 beats/min.

The abnormalities arise if the pulse rates vary:

- **Tachycardia: When pulse rate increases more than normal. A pulse rate over 100 per minute is known as tachycardia**.

This occurs in following conditions:

- Fever
- Infection
- Heart disease
- Diarrhea, vomiting
- Drug toxicity
- Thyrotoxicosis

- **Bradycardia:** When pulse rate decreases than normal, a pulse is known as bradycardia.

This occurs in following conditions:

1. Myocardial infarction
2. Opium poisoning
3. 3. Myxoedema
4. Cerebral tumors

- **Pulse Rhythm**: Rhythm is the regularity of the beats. Rhythm may be nor mal or abnormal. In normal rhythm beats are spaced at equal intervals. So, pulse is always checked for 1 minute to detect dysrhythmias or arrhythmias.

Irregularity in rhythm occurs due to following reasons:

1 Due to myocardium dysfunctioning.

2. Due to problem in SA node or AV node conduction.

3. Dysfunctioning of pacemaker.

The irregular rhythm is present in following conditions:

1. **Atrial fibrillation:** It occurs due to problem in atrium, which causes rapid contraction of atrium, which further affects the contraction of ventricles in rhythm and force.
2. **Ventricular fibrillation:** It occurs due to rapid contraction of ventricles. It is a fatal condition.

3. **Intermittent pulse:** As the name indicates, in this type, beats are missed at regular intervals. There is a difference between the apical and the radical pulse, which is known as pulse defect.
4. **Extrasystole:** In this type, the cardiac contractions occur before due time recommended. Cardiac cycle is known as extrasystole.
5. **Sinus arrhythmia**: In this condition, the pulse rate is rapid during inspiration and slow during expiration.

- **Tension**: It is the degree of compressibility; tension depends upon the resistance offered on the walls of the artery. When the artery is easily compressible, it is said to have as low tension. If it is excessively resistant and firm, it is said to have high tension.

Abnormal tension:

Low tension: The pulse is easily compressed or described as:

1. **Bounding pulse:** Bounding pulse denotes an increased stroke volume, which can be palpated by fingertips slightly. It is often seen with fever, hyperthyroidism and aortic incompetence.

2. **Thready pulse:** The pulse is weak and diminished, which is barely palpated by fingertips. It often occurs with massive hemorthage, shock and aortic stenosis

High tension: When force of blood increases on the walls of artery it is known as high tension, the artery feels cord like hard:

1. **Dicrotic pulse:** There is one heart beat and two arterial pulsations giving the sensation of a double beat. It is due to flabby weak arterial walls

2. **Water hammer pulse or corrigan's pulse:** This type of pulse is found in aortic regurgitation, when valve gets loose. In this condition, when blood is pushed into artery, hen leaks back into the ventricle due to the non closure of the aortic valve. This pulse is also said as collapsing pulse.

- **Volume:** It means strength of the artery. It is the force of the blood felt at each beat. It depends upon the amount of blood in the arteries. If the arteries contain a normal volume of blood, the pulse is said to be full bounding or

large in volume. If the volume of blood is decreased due to hemorhage, the pulse will be weak, thready, small or feeble.

The abnormal volume is seen in the following conditions:

1. **Full bounding pulse:** In anxiety, anemia, exercise or exertional activities due to increase in stroke volume.
2. Pulsus alternans: In this condition rhythm is regular one beat is stronger followed by Weak and again .stronger beat.
3. **Feeble pulse:** In this stroke volume get decreased leading to weak pulse. This occurs in diarrhea, vomit in case of hemorrhagic shock.

ASSESSMENT OF PULSE

Pulse Sites:

There are several sites on the body where a pulse is normally assessed. All arteries have a pulse, but it is easier to palpate (feel) the pulse at certain locations. It is easier to feel the pulse when the artery is near the surface of the skin and when there is firm tissue (such as a bone) beneath the artery. The three most common sites are the radial (wrist), carotid throat) and brachial (inside of elbow).

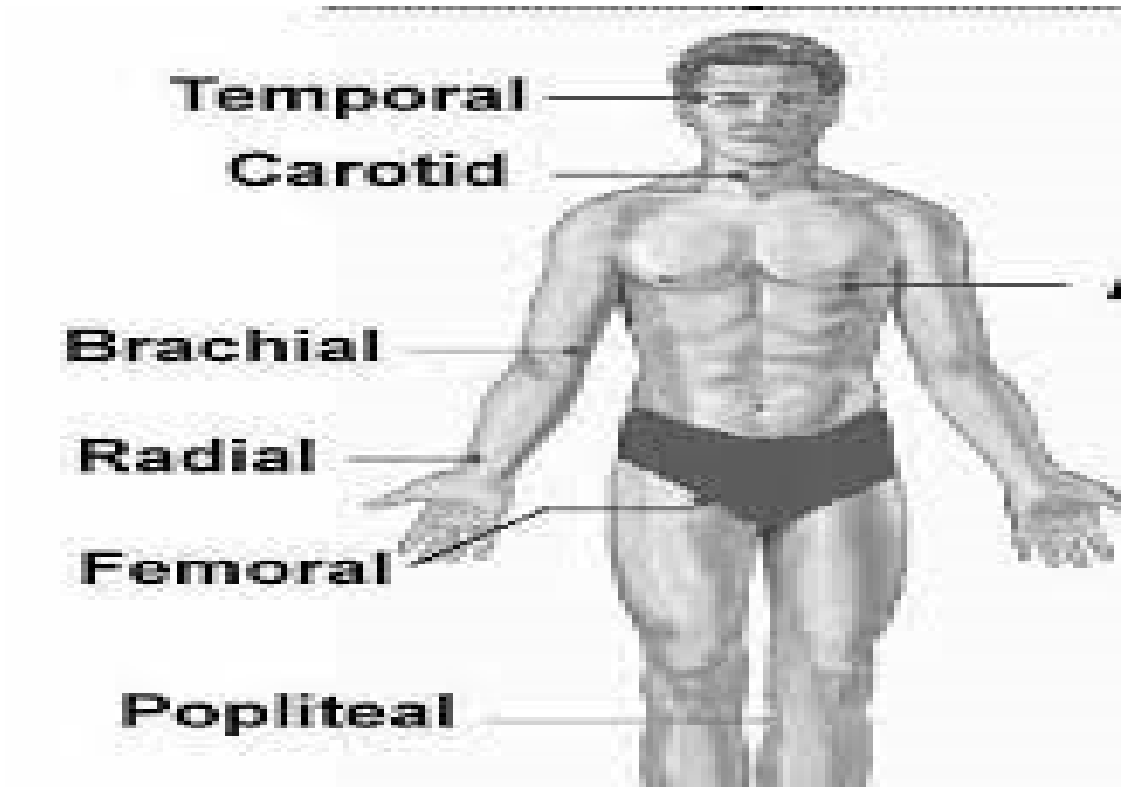

Common peripheral sites for measuring pulse

- **Radial Pulse:** The radial pulse is taken at a point where the radial artery crosses the bones of the wrist. If a patient's hand is turned that the palm is up, the radial pulse is taken on the thumb side of the inner aspect of the wrist.
- **Carotid Pulse:** The carotid pulse is taken on either side of the trachea (wind-pipe). The best location is the grooves located to the right and to the left of the larynx (Adam's apple).
- Brachial Pulse: The brachial pulse is taken in the depression located about one-half inch above the crease on the inside (not the bony side) of the elbow. This site is used when taking a patient's blood pressure.
- **Temporal Pulse**: The temporal pulse is taken in the temporal area on either side of the head. It is located in front of the upper part of the ear. The pulse is felt just above a large, raised bony area called the zygomatic arch.
- **Ulnar Pulse:** Like the radial pulse, the ulnar pulse is taken at the wrist. The radial pulse is taken over the artery on the thumb side of the wrist while the

ulnar pulse is taken on the other side of the wrist. Both pulses are taken on the palm side of the wrist. The radial artery is normally preferred over the ulnar artery for taking the pulse because the radial artery is somewhat larger.

- **Femoral Pulse** The femoral pulse is taken in the groin area by pressing the right or left femoral artery against the ischium (the lower part of the pelvic bones located in the front part of the body).
- **Popliteal Pulse:** The popliteal pulse is taken in the middle of the area located on the inside of the knee (the area opposite the kneecap).
- **Posterior Tibial Pulse**: The posterior tibial pulse is taken at the top of the ankle or Just above the ankle on the back, inside part of the ankie.
- **Apical Pulse**: Unlike the other sites, the apical pulse is not taken over an artery. Instead, it is taken over the heart itself. The apical pulse (actually, the heartbeat) can be felt over the apex of the heart (the pointed lower end of the heart.) This site is located to the (patient's) left of the breastbone and two to three inches above the bottom of the breastbone. The apical pulse is easily heard when a stethoscope is used.
- **Dorsalis Pedis**: Pulse The dorsalis pedis pulse is taken on the top portion of the foot just below the ankle. The pulse is taken in the middle of this area (not to the inside or outside).

Assessing the Pulse Articles Required

1. A watch with a second hand.

2. Recording sheet

3. A pencil or pen

Procedure:

1. Explain the procedure to the To secure cooperation of patient patient. Activity can increase pulse rate.

2. Check whether the patient had just been involved in activity, if yes, allow patient to relax for 10 minutes.

3. Select a pulse site (usually radial) in case of supine position, keep the arm resting over chest. In sitting position, keep the arm resting over thigh with palm facing downward.

4. Palpate the pulse and count by placing the tips of first three fingers highly over pulse site.

5. Never use thumb for counting pulse.

6. Count the pulse for one full minute by using second hand of wrist watch.

7. Assess the rhythm and strength of the pulse.

8. Document the findings on the patient's chart.

9. wash hands.